



**DATE PRESENTING CLINICAL SIGNS**

1.12.26 History: Recently re-presented for evaluation of an increased frequency and severity of coughing episodes. The cough is consistently triggered by excitement and physical activity, and a similar cough was easily elicited with tracheal palpation during examination. She has a known holosystolic murmur consistent with degenerative mitral valve disease. A previous radiology consultation noted concerns for left-sided cardiomegaly. In August, thoracic radiographs raised suspicion for incipient congestive heart failure, and Pixie was started on furosemide, which she remains on currently. The owner was also instructed to monitor her respiratory rate at home.

**PATIENT**

Pixie Manukonga

**SPECIES**

Canine

**BREED**

Chihuahua

**SEX**

FS

**AGE**

12.23.15

**WEIGHT**

16.4lbs

-Pertinent abnormal PE/Chem/CBC/UA Results: ALP 1121.  
-Current medications: Furosemide 10 mg/ml: Give 1.7 ml orally once daily as a general diuretic.  
-Sedation used: Not required to complete full diagnostic ultrasound.  
-Pertinent previous ultrasound results:  
-STAT: Not requested.  
-Imaging performed by: Andi Parkinson, BS, RDMS.

**RADIOGRAPHIC FINDINGS** \*NOTE: Images submitted for supplemental information only.

Subjective cardiomegaly; however, pectus-excavatum is present. No obvious evidence of CHF.

**ECHOCARDIOGRAM FINDINGS** \*limited images obtained due to abnormal chest confirmation. Only left-sided views available.

2D, m-mode, color flow and doppler imaging is available. Normal mitral valve leaflets with no prolapse into the left atrial lumen. Trivial mitral regurgitation with no left atrial dilation. Normal LV diameter with adequate myocardial function. The tricuspid valve appears normal with no obvious tricuspid regurgitation. Normal right atrial and ventricular diameter and morphology indicating no overt evidence of pulmonary arterial hypertension. The pulmonic and aortic valves are normal in morphology and mobility. Normal pulmonic and aortic outflow velocities with laminar flow. No obvious aortic or pulmonic insufficiency. No pericardial or pleural effusion noted. No obvious cardiac masses.

**INTERPRETED BY**

Maggie Machen Lamy,  
DVM, DACVIM  
(Cardiology)

**CARDIAC CHART**

**HOSPITAL NAME**

Northwind AH

**REFERRING VET**

Dr. Wilson

**INVOICE**

46397

CANINE CARDIAC PARAMETERS	MR VMAX (m/s)	TR VMAX (m/s)	LA/AO (Boon method)	LA/AO (Heart Base; Swe)	FS (%)	EF (%)	EPSS (cm)
NORMAL PARAMETER	4.5-5.5	<2.7	1.3	<1.6	28-40	40-100	<0.6
PATIENT	NA	NA	NM	1.2	52	85	NM
CANINE CARDIAC PARAMETERS	HR (BPM)	AV VMAX (m/s)	PV MAX (m/s)	BODY WEIGHT (kg)	LA 2D short axis Base view (cm)	LVIDd Avg; 2D and m-mode short axis (cm)	LVIDs Avg; 2D and m-mode short axis (cm)
NORMAL PARAMETER	50-100	0.7-1.7	0.7-1.6	BELOW	BELOW	BELOW	BELOW
PATIENT	60	1.4	NM	7.4	1.6	2.3	1.1
*Normal chamber parameters expressed as a mean value (SD)				3	1.27 (5.3)	2.46 (2.46)	1.36 (5.5)
<b>BODY WEIGHT DEPENDENT PARAMETERS</b>				5	1.40 (4.5)	2.74 (5.2)	1.60 (4.7)
*Note: All measurements based upon multi-modal images and methods. An average value is reported.				10	1.50 (3.8)	3.27 (3.5)	2.06 (3.1)
				15	1.83 (2.0)	3.71 (2.4)	2.43 (2.1)
				20	2.02 (1.9)	4.14 (2.2)	2.80 (2.0)
Adapted from June Boon, Veterinary Echocardiography, 1998				25	2.18 (2.4)	4.48 (2.9)	3.10 (2.5)
Rishniw M and Hollis NE, J Vet Intern Med 2000; 14:429-435				30	2.33 (3.3)	4.83 (3.9)	3.39 (3.4)
Hansson et al, Vet Rad and Ultrasound 2002				35	2.48 (4.3)	5.17 (5.0)	3.69 (4.5)
Bonagura et al. Echocardiography: principles of interpretation, Vet Clin North Am 15:1177, 1995				40	2.62 (5.2)	5.48 (6.1)	3.96 (5.4)
				50	2.88 (7.1)	6.07 (8.3)	4.46 (7.4)

### **INTERPRETATION OF THE FINDINGS & FURTHER RECOMMENDATIONS**

Overtly normal cardiac dimensions and function, with no obvious dysfunction or dilation of the left heart. No significant valvular leaks are visualized, and no evidence of pulmonary hypertension. Bradycardia is noted throughout the study. An ECG should be considered if this is a persistent finding.

No cardiac medications are indicated at this time as the cough is certainly non-cardiac in origin and Lasix can and should be discontinued. Continued work up for infectious/inflammatory respiratory causes is recommended. Options include Baytril or similar antibiotic, anti-inflammatory prednisone, aggressive hydrocodone, etc. If refractory, may consider TTW/BAL for further information.

Due to abnormal chest confirmation, radiographs are often difficult to interpret. These films should be used as a baseline for future comparison.

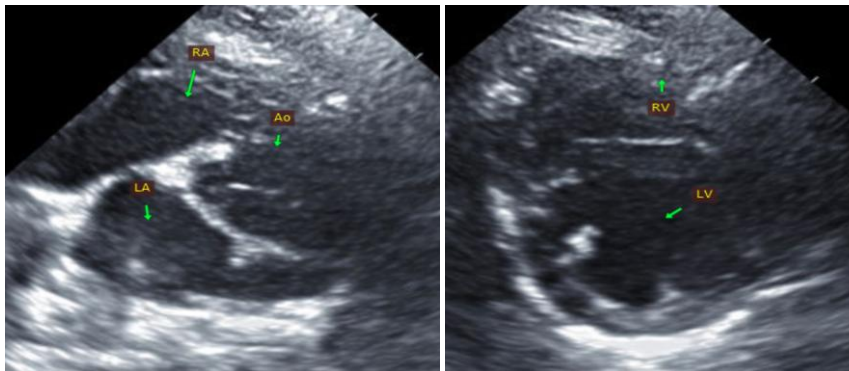
Monitor for development of a heart murmur, acutely progressive cough, labored breathing, exercise intolerance or collapse episodes.

### **PLAN**

Discontinue Lasix. Baseline BP recommended. Further cough workup as discussed.

Chronic respiratory issues can lead to pulmonary hypertension if poorly controlled and a recheck echocardiogram is recommended should any exertional syncope/dyspnea occur, or a murmur be noted in the future.

### **IMAGES**



**The information and recommendations provided are based on the images presented by the referring veterinarian. No evaluation can be communicated regarding pathology that was not visible in the image/video clips provided.**

Thank you for this referral. This report was generated using transcription software, and minor dictation errors may be present. If the clinical or image interpretation does not parallel your findings or if I can be of any further assistance, please contact me.

**Maggie Machen Lamy, DVM**  
**Diplomate of the American College of Veterinary Internal Medicine (Cardiology)**  
**info@sonopath.com**